



# Parametric Response Mapping: a voxel-based analysis of quantitative diffusion MRI changes for individualized assessment of primary breast cancer response to therapy

CR Meyer<sup>1</sup>, TL Chenevert<sup>1</sup>, CJ Galbán<sup>1</sup>, TD Johnson<sup>2</sup>, DA Hamstra<sup>3</sup>, A Rehemtulla<sup>3</sup>, BD Ross<sup>1</sup>  
 Radiology<sup>1</sup> and Radiation Oncology<sup>3</sup>, School of Medicine and School of Public Health<sup>2</sup>,  
 University of Michigan, Ann Arbor, MI 48109, USA

Poster# 2223



## Introduction

Ideally a patient's response to neoadjuvant chemotherapy could be observed noninvasively, in the first 2-3 weeks of treatment using an imaging to provide feedback related to the effectiveness of the chosen chemotherapy regimen. This capability would permit individualization of patient care by supporting the opportunity to tailor chemotherapy to a each patient's response. Functional diffusion mapping (fDM), now called Parametric Response Mapping (PRM) was recently proposed as an MRI-imaging biomarker for quantifying early brain tumor response to therapy [1-3]. This approach quantifies local apparent diffusion coefficient (ADC) changes in tumors using a voxel-based analysis implemented by rigid registration of the patient's head between interval exams. Here we have extended this approach by demonstrating ADC changes in 3 of 5 primary breast cancer patients measured in response to onset of neoadjuvant chemotherapy from interval exams separated by only 8-11 days.

## Methods

This is a double-blinded study where the blinded estimates of response to therapy have been obtained from registered, voxel-by-voxel, quantitative apparent diffusion coefficient (ADC) scans which were then used to predict individual patient response to the first cycle of neoadjuvant chemotherapy. Likewise in a blinded fashion the breast oncologist independently estimated the clinical response of the patient at the end of the first adriamycin/cyclophosphamide (AC) phase before initiation of the second phase of therapy involving Taxotere.

In this protocol patients with breast CA that have elected neoadjuvant chemotherapy prior to surgery receive 2 baseline exams, typically within a 15 minute interval where the patient is removed from the scanner and then repositioned for the second scan; these short interval exams are used to observe a sample of the null change distribution since no macroscopic changes have occurred to the tumor in this interval. The initiation of the first cycle of chemotherapy (AC) is typically within one day of the short interval exams. Another MRI exam is obtained 8-11 days post-initiation. Tumor volumes of interest (VOI) were drawn on the anatomical image volume and were warped from the anatomical volume onto one of the two pretherapy (pre-Tx) diffusion volumes denoted as the reference. Subsequent registrations either between the two pre-Tx exams or the two pre- and post-Tx scans are also warped to account for repositioning deformations to the breast as well as any small compartmental changes to the tumor.

Warping is accomplished using thin plate splines where the degrees of freedom (DOF) of the warp is related to the local mutual information density and volume of the tumor. The user only picks the loci of 3 control points in the second tumor volume that approximates their loci in the reference tumor volume. The multiscale registration first implements rigid body registration, then low DOF warping, and finally full DOF warping [4].

## Methods, cont'd...

ADC volumes are computed from the interleaved b0 and b800 MRI DWI acquisitions. For each pair of registered ADC images a 128x128 joint density histogram (JDH) is constructed by incrementing the count of the 2D histogram defined by the two ADC values of the registered tumor. For the JDH of the two pre-Tx exams, inevitable sample bias is removed and variance is generalized, i.e. increased, by adding the transpose of its JDH to itself. Then a percentile threshold of the null distribution is estimated; here we demonstrate the use of the 97.5<sup>th</sup> percentile (Figure 2, top left).

Next, the same process is repeated using one of the short interval, pre-Tx exams and the post-Tx scan. This distribution represents the treatment effect (Figure 2, top right) and clearly reveals that ADC values have increased in several ways: first the mean has moved upwards, and secondly there are many more counts above the 97.5<sup>th</sup> percentile line derived from the null distribution. For each patient the first two rows of the table (Figure 2, middle) show the incremental percent increase in counts above the null's 97.5<sup>th</sup> and 95<sup>th</sup> percentile for the Treatment Effect distribution.

At this stage increases above both the 97.5<sup>th</sup> and 95<sup>th</sup> percentile correlate perfectly with clinically assessed partial response (cPR), while decreases correlate perfectly with clinically assessed stable disease (cSD) for the first cycle of chemotherapy for these first 5 patients; the chances of our obtaining these 5 outcomes randomly is 3%. The bottom row of images in Fig. 2 shows a single slice of each the anatomical reference breast exams overlaid with red-green-blue mask of the tumor. Here red indicates the presence of voxels whose ADC changes (postTx minus preTx) are greater than the 97.5<sup>th</sup> percentile of the null distribution (regions of effect, i.e. cell kill, as well as limited noise) green indicates voxels whose changes are within the 2.5<sup>th</sup> - 97.5<sup>th</sup> percentiles (regions of no significant change) and blue indicates changes that are below the 2.5<sup>th</sup> percentile of the null (regions of effect, i.e. continued tumor growth, as well as limited noise). Responders are shown in the yellow columns along with the %increase of counts above that expected from the null hypothesis. Non-responders shown in the orange columns demonstrate the corresponding decrease.

Recall that 8-11 days post-initiation of the first (AC) cycle of chemotherapy is very early in assessing tumor change compared with any other technique. Presumably these effect changes increase roughly proportionally to the time interval between the pre-therapeutic and post-therapeutic scans for several weeks. It is very encouraging indeed that we may reliably see changes within 8-11 days. Moreover for these five patients the 97.5<sup>th</sup> percentile corresponds to ADC changes whose mean is not significantly different than  $\pm 0.5 \cdot 10^{-3} \text{ mm}^2/\text{s}$ , the same threshold used for the successful differentiation of PD and SD in glioblastoma multiforme brain cancer patients assessed with the similar methodology in our previous publications [1-3].

## References

- Moffat, B et al (2005) *Functional diffusion map: a noninvasive MRI biomarker for early stratification of clinical brain tumor response*, Proc Natl Acad Sci USA **102**(15):5524-5529.
- Hamstra, DJ, et al (2005) *Evaluation of the functional diffusion map as an early biomarker of time-to-progression and overall survival in ...*, Proc Natl Acad Sci USA **102**(46):16759-16764.
- Hamstra, DA et al (2008) *The functional Diffusion Map (fDM): an early imaging biomarker for overall survival in high-grade glioma*, J. Clin Oncol **26**(20):1-9.
- Meyer, CR et al (1997) *Demonstration of accuracy and clinical versatility of mutual information for automatic multimodality image fusion ...*, Medical Image Analysis **1**(3):195-206.

## Results

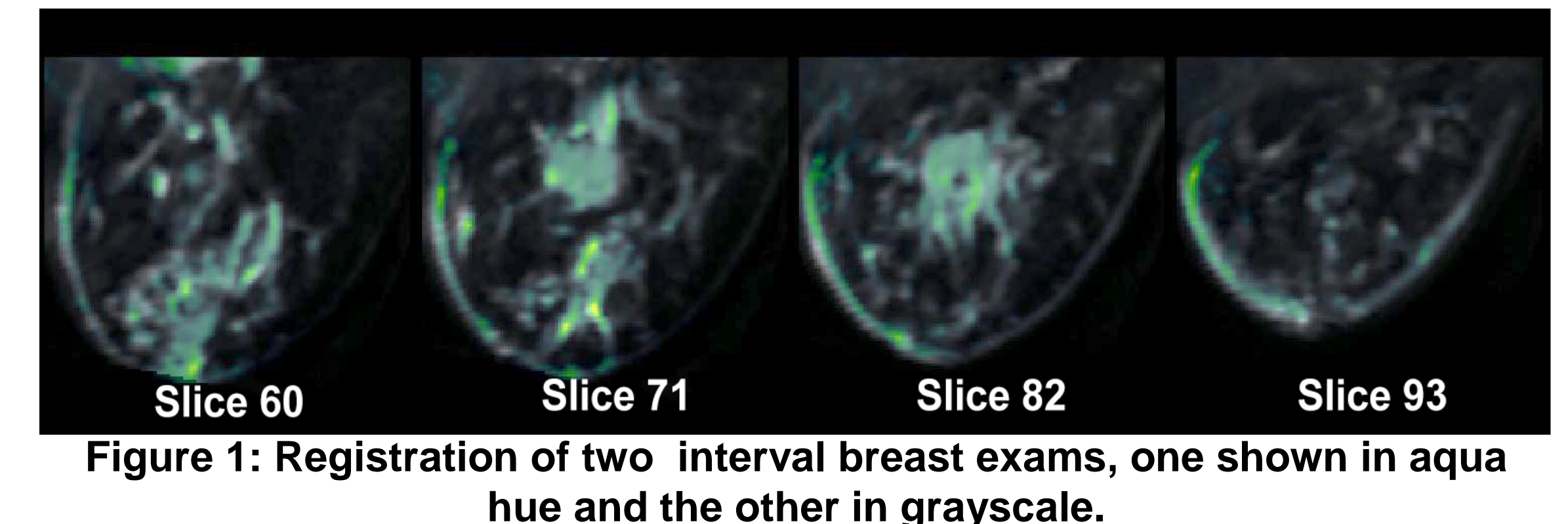


Figure 1: Registration of two interval breast exams, one shown in aqua hue and the other in grayscale.

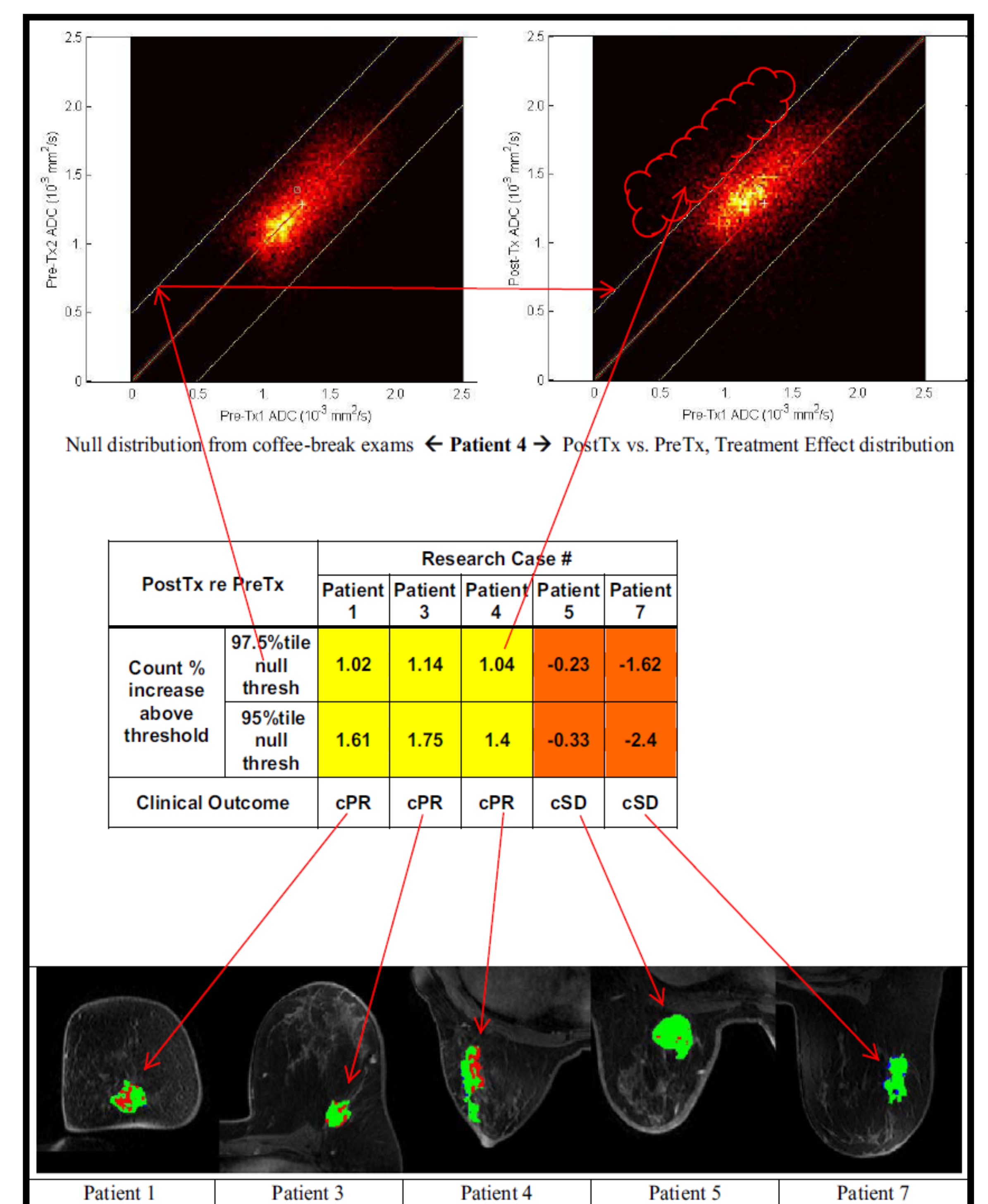


Figure 2: Five patients are evaluated for response. The yellow columns show responders (%counts above null threshold increased); non-responders shown in orange columns decreased.

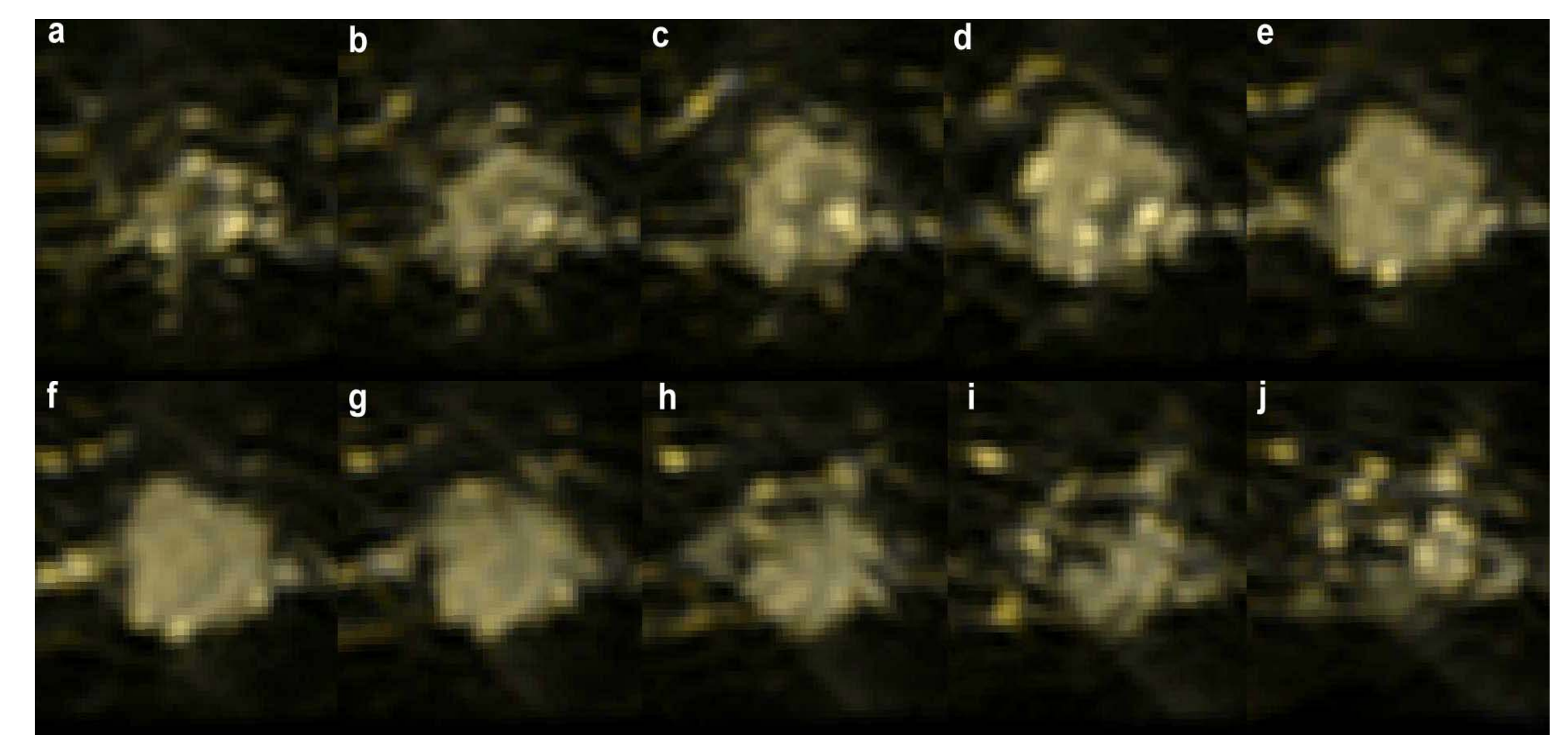


Figure 3: Adjacent slices from a registration of only the lesion in interval breast exams, one shown in yellow and the other in gray

Funded by NIH grants 1P01CA85878 & 1P01CA87634